

15._Agussalim_Bukhari- Nurpudji3.pdf

by

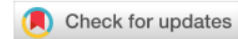Submission date: 13-Jan-2023 02:00PM (UTC+0700)

Submission ID: 1992178953

File name: 15._Agussalim_Bukhari-Nurpudji3.pdf (774.34K)

Word count: 6847

Character count: 36465

40
RESEARCH ARTICLE

The effect of snakehead fish extract on acute wound healing process in hyperglycemic rats [version 1; peer review: 2 approved with reservations]

Nurpudji Astuti Taslim¹, Caroline Prisilia Marsella¹, Agussalim Bukhari¹, Muhammad Husni Cangara², Andi Makbul Aman³, Aminuddin Aminuddin¹, Mardiana Madjid⁴

¹Nutrition, Hasanuddin University, Makassar, Indonesia

²Anatomical Pathology, Hasanuddin University, Makassar, Indonesia

³Internal Medicine, Hasanuddin University, Makassar, Indonesia

⁴Nutrition, Wahidin Sudirohusodo Hospital, Makassar, Indonesia

43

V1 First published: 24 Mar 2022, 11:356
<https://doi.org/10.12688/f1000research.109196.1>

Latest published: 24 Mar 2022, 11:356
<https://doi.org/10.12688/f1000research.109196.1>

Abstract

Introduction: Wound healing is an integrated response to tissue injury. A hyperglycemic state can lead to delayed wound healing process. Snakehead fish (*Channa striata*) is native freshwater fish of South East Asia that contains high protein, albumin, and several micronutrients. The aim of this study is to evaluate the efficacy of snakehead fish extract on acute wound healing process in streptozotocin-induced hyperglycemic rats.

Methods: This study was an experimental trial on the hyperglycemic animal model. Thirty male Wistar streptozotocin-induced rats were divided into two groups which were then given snakehead fish extract (Pujimin Plus®) 81mg a day for 10 days after wound infliction in intervention group and carboxymethyl cellulose sodium (Na-CMC) in control group. On day 0, day 3, and day 10 after wound infliction, the histological changes (number of neutrophil and fibroblast, and vascular changes of the wounded tissues) of each group were analyzed. Assessments were also made on erythema and crust formation by the visual scores.

Results: Our study showed significant increase in the number of fibroblasts on day 3 in the snakehead fish extract group compared to control group (40.33 ± 10.13 vs. 24.60 ± 10.25 , $p = 0.04$). There were no significant differences in vasculature and neutrophil numbers. The results also showed snakehead fish extract could decrease mean erythema visual score on day 3 (3.24 ± 0.25 vs. 3.64 ± 0.35) and decreased crust formation on day 5 (3.36 ± 0.75 vs. 3.44 ± 0.83).
Conclusions: Snakehead fish extract has potential effect to accelerate the wound healing process by increasing fibroblast, decreasing

Open Peer Review

Approval Status ? ?

	1	2
version 1	?	?
24 Mar 2022	view	view

1. **Abdunnur Abdunnur**⁴⁴, Mulawarman University, Samarinda, Indonesia
2. **Ahmad Farouk Musa**⁶², Monash University Malaysia, Bandar Sunway, Malaysia
Shaik Farooq, Monash University Malaysia, Bandar Sunway, Malaysia

14 Any reports and responses or comments on the article can be found at the end of the article.

erythema, and decreasing crust formation in streptozotocin-induced hyperglycemic rats.

Keywords

Snakehead fish, wound healing, hyperglycemia, fibroblast, neutrophil, vascular changes

Corresponding author: Nurpudji Astuti Taslim (pudji_taslim@yahoo.com)

Author roles: **Taslim NA:** Conceptualization, Funding Acquisition, Investigation, Project Administration, Supervision, Writing – Original Draft Preparation, Writing – Review & Editing; **Marsella CP:** Project Administration, Writing – Original Draft Preparation; **Bukhari A:** Validation, Writing – Original Draft Preparation, Writing – Review & Editing; **Cangara MH:** Formal Analysis, Project Administration; **Aman AM:** Formal Analysis, Writing – Original Draft Preparation; **Aminuddin A:** Formal Analysis, Writing – Original Draft Preparation; **Madjid M:** Formal Analysis, Writing – Original Draft Preparation

Competing interests: No competing interests were disclosed.

Grant information: This work has been funded by: Universitas Hasanuddin (915/UN4.22/PT.01.03/2021).

The funders had no role in study design, data collection and analysis, decision to publish, or preparation of the manuscript.

Copyright: © 2022 Taslim NA *et al.* This is an open access article distributed under the terms of the [Creative Commons Attribution License](#), which permits unrestricted use, distribution, and reproduction in any medium, provided the original work is properly cited.

How to cite this article: Taslim NA, Marsella CP, Bukhari A *et al.* **The effect of snakehead fish extract on acute wound healing process in hyperglycemic rats [version 1; peer review: 2 approved with reservations]** F1000Research 2022, 11:356 <https://doi.org/10.12688/f1000research.109196.1>

First published: 24 Mar 2022, 11:356 <https://doi.org/10.12688/f1000research.109196.1>

Introduction

Prolonged hyperglycemic conditions can cause various complications, both macrovascular and microvascular. Patients tend to experience impaired wound healing processes, which can develop into chronically infected wounds. Chronically infected wounds will increase the risk of systemic infection leading to increase in the morbidity and mortality of patients. Therefore, it is necessary to have a good understanding of wound healing process and appropriate interventions to support a good wound healing process.^{1,2} Physiologically, wound healing is achieved through four phases: hemostasis, inflammation, proliferation, and remodeling. All these phases occur in an integrated way and require an optimal environment and conditions. In hyperglycemia conditions, systemic inflammation leads to increase oxidative stress, impairs migration of leukocytes to the wound area, and inhibit extracellular matrix synthesis.²

Protein plays an important role in regulating the body's homeostatic processes. They are the constituent components of immune cells, cytokines, tissues, and enzymes that involved in the physiological process of wound healing. Neutrophils, monocytes, and macrophages release pro-inflammatory cytokines and growth factors such as platelet-derived growth factor (PDGF), transforming growth factor- β (TGF β), and fibroblast growth factor (FGF), which are involved in the activation of fibroblasts and epithelial cells. PDGF stimulates fibroblast functions and collagenase expression. TGF β controls the regulation signal of extracellular matrix deposits, increasing the production of matrix proteins and downregulation of protease enzymes. In the wound area, there is an increase in the level of hypoxia-inducible factor (HIF) in cells. HIF will bind to specific DNA and stimulate specific transcription genes such as vascular endothelial growth factor (VEGF). VEGF is the main vascular growth factor in the entire angiogenesis process.³

Snakehead fish (*Channa striata*), a native freshwater fish in South East Asia, contains high protein and albumin which act as antioxidants and constitutive tissue components. Snakehead fish also contains micronutrients such as zinc, iron, calcium, and magnesium which have role in the immune system and wound healing process. Administration of snakehead fish significantly increased fibroblasts in oral mucosal wounds of Wistar rats.⁴

Although there have been several studies regarding the benefits of snakehead fish extract on wound healing in diabetics, the wounds in those studies have different sizes and conditions. The difference in type of wounds, wound size, food intake factors, and metabolic condition can be confounding in assessing the effect of snakehead fish extract on wound healing.⁴⁻⁶

We developed snakehead fish extract formula (Pujimin Plus[®]) as a protein and micronutrients source with an aim to reduce hypoalbuminemia among patients and improve the wound healing process. However, the exact mechanism of how this extract improves wound healing remains unclear.

Therefore, this study was conducted to see the effect of snakehead fish extract on healing acute wound tissue in hyperglycemic rats by analyzing macroscopic and microscopic changes in wound tissue.

Methods

Study design

This study used an animal experimental model.²⁶ It was approved by the Health Research Ethics Commission in Faculty of Medicine, Hasanuddin University, Indonesia with number 209/UN4.6.4.5.31/PP36/2021 and registered in *preclinicaltrials.eu* with ID PCTE0000240.

Animal model

Forty healthy male Wistar rats (*Rattus norvegicus*) weighing 150–200 g and aged 8–10 weeks were used in this study. Rats were kept at Molecular Biology and Immunology Laboratory, Faculty of Medicine, Hasanuddin University and housed in six plastic cages (five rats per cage) at room temperature ($22 \pm 2^\circ\text{C}$) for 1 week in 12-hour light-dark cycle of 12 hours with free access to food and water. They were fed a conventional rat diet with Comfeed ADII and had an unlimited supply of drinking water.

Hyperglycemia induction was performed by using intraperitoneal injection of Streptozotocin 8.5 mg. Blood glucose levels were checked 24 hours after streptozotocin induction, a level > 200 mg/dL confirmed hyperglycemia. Blood glucose level was re-checked prior to sample collection.^{7,8}

Wound infliction

Throughout the experimental study, every effort was made to minimize the pain and distress of the animals. Wound was inflicted after confirmation of hyperglycemic status. Prior to the wound infliction, the dorsal hair was removed using hair remover gel, the area was disinfected using a 70% alcohol swab and then allowed to dry. The rats were anaesthetized with

ketamine (80-100 mg/kg) intraperitoneally. Wound was inflicted on the bare area of dorsal skin using a punch biopsy with a diameter of 8 mm to the depth of deep fascia.^{9,10}

Intervention of the rats⁵⁵

The rats were divided into 2 groups, intervention and control groups. After wound infliction, the rats in intervention group were given snakehead fish extract (Pujimin Plus[®]) at a dose of 81 mg/day by oral gavage for the next 10 days (Table 1). Those in control group were given carboxymethyl cellulose sodium (Na-CMC) solution as a placebo.^{11,12} Pujimin Plus[®] capsule is a patent trademark of snakehead fish extract with patent number IDM000301812.

Macroscopic observations

The wounds were observed daily and photo documentation was done on days 0, 3, 5, 7, and 10. The lesions on each rat were rated by 3-blinded physicians as investigators. The observation was performed twice and assessed by a supervisor in order to reduce the reliability problem. The lesion were rated using the following 5-point-erythema score¹³: 0 = no red color at all, 1 = light red just visible, 2 = clearly red, 3 = dark red, but not whole area, 4 = dark red widespread. Likewise, 6-point-crust formation score¹⁴ was also followed: 0 = 100% crust formation, 1 = 76–99% crust formation, 2 = 51–75% crust formation, 3 = 26–50% crust formation, 4 = 1–25% crust formation, 5 = 0% i.e. no crust formation.

Sample collection⁵³

Tissue samples were collected from 5 rats of each group on day 0, day 3, and day 10 after wound infliction. The rats were sacrificed using isoflurane inhalation (0.05 µg/kg/day) by placing the rat in a box and waiting for 5-10 minutes. The process of extracting wound tissue involved making an excision on the skin with a scalpel number 20 at a distance of 1.5 cm from all edges of the wound. Tissue samples were stored in a container containing neutral buffered formalin 10%

Table 1. The content of snakehead fish extract (Pujimin Plus[®]) per capsule (750 mg).

Parameter	Content	Unit
Protein	78.99	%
Albumin	39.34	%
Water	3.00	%
Aspartate	62191	ppm
Glutamate	109447	ppm
Serin	35678	ppm
Glycine	51839	ppm
Histidine	23596	ppm
Arginine	59775	ppm
Threonine	43552	ppm
Alanine	43525	ppm
Proline	28364	ppm
Valine	39261	ppm
Tyrosine	36890	ppm
Isoleucine	35792	ppm
Leucine	64527	ppm
Phenylalanine	46993	ppm
Lysine	72948	ppm
Cysteine	2581	ppm
Methionine	29967	ppm
Zinc	29	ppm
Iron	43	ppm
Magnesium	1041	ppm
Calcium	4112	ppm

and then transported to the Anatomical Pathology Laboratory of the Hasanuddin University Hospital for histological examination with hematoxylin and eosin (H&E) staining. H&E stain is a type of histological stain that clearly stains cell structures including the cytoplasm, nucleus, organelles, and extra-cellular components.²⁵ Histological analysis was carried out by assessing the number of neutrophils, fibroblast, and vascular changes (arterioles and capillaries) in three fields of view with 40× magnification.

Statistical analysis

Descriptive statistics and bivariate analysis were performed using independent samples t-test for parametric and Mann-Whitney U test for nonparametric analysis. Descriptive statistics of rats were presented for body weight and blood glucose level after 24 hours of streptozotocin induction. Bivariate analysis was performed to assess the difference of the mean of wound healing level between groups (number of neutrophils and fibroblast, vascular changes, and macroscopical scores). The data were entered into statistical package for social sciences (IBM SPSS Statistics, RRID:SCR_019096) version 23.0 database for Windows. The p-values < 0.05 were considered statistically significant in all analyses.

Results

Samples characteristics

A total of 30 male Wistar rats (*R. norvegicus*) were divided into 2 groups (snakehead fish extract group and control group). No rats were dropped out, nor did any rat die during the research. All rats experienced hyperglycemia with a target of blood glucose level >200 mg/dL after the first streptozotocin induction (Table 2). The body weight and blood glucose level 24 hours after streptozotocin induction were measured for both groups.

Macroscopic assessment of wound tissue

Macroscopic analysis was done by assessing the presence of erythema and the formation of crusts in wounds on day 0, 3, 5, 7, and 10. The highest mean of erythema visual score was found on day 3, which decreased day by day until no erythema was found (score 0) on day 10 in both the groups. The erythema scores of control group on day 3, 5, 7, and 10 were higher than the extract group, but there were no significant differences between the two groups (Table 3).

In general, the mean crust visual score of extract group was lesser than the control group. The increase of mean crust visual score of extract group occurred on day 3 (1.84±0.22) and the highest score was noted on day 5 (3.36±0.75), which then decreased on day 7 (1.04±0.29) until there was no crust formation (score 0) on day 10. Similarly, in control group, the highest mean crust visual score was noted on day 5 (3.44±0.83) which decreased on day 7 (1.18±0.27) until there was no crust formation on day 10. There was no significant difference between the two groups (Table 4).

Histological analysis of wound tissue

Microscopic observations for counting the number of neutrophils, fibroblasts, and vascular changes (or angiogenesis processes (the growth of new blood vessels from existing vessels)) were performed at 40× magnification. As noted in Table 5, the average number of neutrophils in extract group reached the highest value on day 3 (54.47±6.27) then declined on day 10 (3.6±2.43). Similar to extract group, the highest mean of neutrophils in control group were observed

Table 2. Basic characteristics of rats.

	Control (Mean + SD)	Extract (Mean + SD)	p-value
Body Weight (grams)	173.20 ± 7.47	171.60 ± 6.85	0.786
Blood glucose level after 24 h streptozotocin induction (mg/dL)	251.00 ± 22.14	238.20 ± 27.16	0.439

Table 3. Mean erythema visual score.

Group	Day 3	Day 5	Day 7	Day 10
	Mean (SD)	Mean (SD)	Mean (SD)	Mean (SD)
Control	3.64 (0.35)	2.66 (0.48)	1.10 (0.49)	0.00 (0.00)
Extract	3.24 (0.25)	2.50 (0.37)	0.96 (0.52)	0.00 (0.00)
p-value	0.292	0.283	0.787	0.000

Table 4. Mean crust visual score.

Group	Day 3	Day 5	Day 7	Day 10
	Mean (SD)	Mean (SD)	Mean (SD)	Mean (SD)
Control	1.90 (0.30)	3.44 (0.83)	1.18 (0.27)	0.00 (0.00)
Extract	1.84 (0.22)	3.36 (0.75)	1.04 (0.29)	0.00 (0.00)
p-value	0.841	0.490	0.933	0.000

Table 5. Number of neutrophils, fibroblasts and vascular changes per field of view in experimental animals.

Histological view		Control Mean (SD)	Extract Mean (SD)	P value
Neutrophils	Day 0	21.00 (5.48)	19.67 (3.57)	0.661
	Day 3	59.00 (21.73)	54.47 (6.27)	0.666
	Day 10	5.58 (2.63)	3.60 (2.43)	0.279
Fibroblasts	Day 0	1.33 (0.71)	1.87 (0.18)	0.141
	Day 3	24.60 (10.25)	40.33 (10.13)	0.040*
	Day 10	44.83 (14.81)	42.07 (6.39)	0.715
Vascular changes	Day 0	6.33 (2.26)	5.67 (2.50)	0.670
	Day 3	13.53 (4.84)	14.80 (3.50)	0.648
	Day 10	4.08 (2.52)	3.87 (1.17)	0.868

*p<0.05.

on day 3 (59 ± 21.27) then declined on day 10 (5.58 ± 2.63). There were no significant differences in neutrophil numbers in both the groups.

The angiogenesis processes on day 3 increased to 14.80 ± 3.50 in extract group and 3.53 ± 4.84 in control group then decreased to 3.87 ± 1.17 in extract group and 4.08 ± 2.52 in control group on day 10. There were no significant differences between both groups. Based on Table 5, the mean number of fibroblast cells in extract groups on day 0 and day 3 were higher than the control group. In extract group, observations on day 0 showed the mean number of fibroblast cells were 1.87 ± 0.18 , which then increased to 40.33 ± 10.13 on day 3, and the highest number 42.07 ± 6.39 was observed on day 10. The mean number of fibroblasts in extract group on day 3 had a significant difference compared to the control group ($p=0.040$). On day 0 and day 3, the mean number of fibroblasts in control group were lesser than the extract group with the value 1.33 ± 0.71 and 24.60 ± 10.25 respectively. On day 10, the mean number of fibroblasts in control group were higher than extract group but there was no significant differences ($p=0.715$).

Figure 1 shows the histological changes of the wound healing process over time. Histological images on day 0 were collected from wounded skin tissue of the rats after 2 hours of wound infliction. The clot was formed as a result of hemostasis process (Figures 1A-1B). On day 3, infiltration of inflammatory cells in wound tissue was seen, particularly neutrophils and several lymphocytes. More active fibroblasts migrated into the wound area of the extract group on day 3 compared to the control group (Figures 1C-1D). The proliferation phase represents a proliferation of both epithelial and dermal elements which results in re-epithelialization of the wound and laying of the primary extracellular matrix. On day 10, the number of inflammatory cells were less and the layer of the epidermis was thicker. The granular tissue was full of cells and arteries completely occupied the wound in both groups. The histological images showed a complete re-epithelialization with dense collagenous matrix (Figures 1E-1F).

22 Discussions

Wound healing is the complex process that includes several phases such as hemostasis, inflammatory, proliferative, and remodeling. This whole phase requires optimal environment and conditions to be able to take place properly. In conditions of hyperglycemia, systemic inflammation occurs which increases the oxidative stress, impaired migration of leukocytes to the wound area, endothelial cell dysfunction, and decreased synthesis of extracellular matrices. This condition can interfere with the wound healing process.² Snakehead fish (*C. striata*) extract has high nutritional value and has shown various benefits in increasing albumin levels, lowering inflammatory status, and aiding the wound healing process.^{12,15-17}

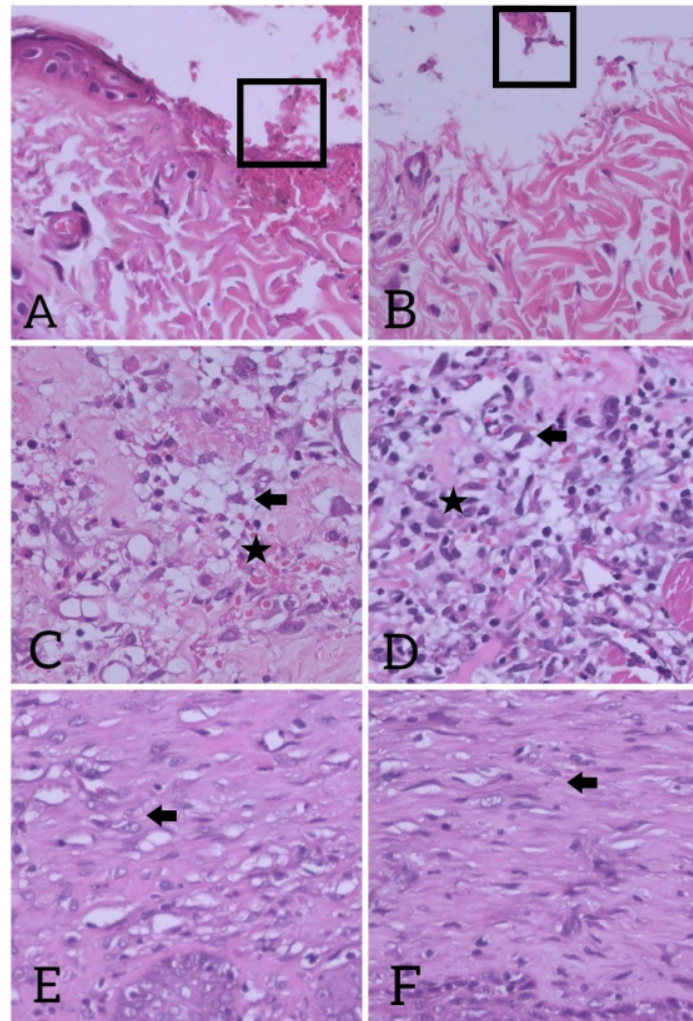


Figure 1. Histological view of wound tissue of hyperglycemic rat. (A) Control group on day 0; (B) Extract group on day 0. Clotting blood (square) in wound area; (C) Neutrophil infiltration (star), lymphocyte infiltration, and fewer active fibroblast (arrow) in control group on day 3; (D) More active fibroblasts (arrow) with neutrophil infiltration (star), lymphocyte infiltration seen in intervention group on day 3; (E) In control group on day-10; (F) Fibroblast (arrow) with dense extracellular matrix seen in intervention group on day-10. H&E stain, magnification 40 \times . Fibroblast is spindle-shaped cells (flat ²¹ elongated) with oval-shape nucleus. The cytoplasm is basophilic and is stained in purplish blue by H&E stain. During stress, fibroblasts adapt to their environment and have the ability to respond and send local signals. On day 3 after wound creation (Figs. C and D), fibroblasts transformed to active forms with euchromatic nuclei and obvious cytoplasm. This form plays role in wound healing to sends local signal, synthesizes the extracellular matrix, and produces the structural stroma for tissue. On day 10 (Figs. E and F), in remodeling phase, fibroblasts became to inactive forms with small cytoplasm and reduced amount of rough endoplasmic reticulum. The extracellular matrix and stroma became denser in this phase.

In the inflammatory phase ⁵ of the wound healing process, there is an increase in the number of neutrophils in the tissue. Neutrophils ⁴ play a role in fighting infections through the phagocytosis of pathogens and foreign bodies as well as secreting inflammatory mediators such as Tumor Necrosis Factor Alpha (TNF- α) and Interleukin-1 (IL-1) that can attract and activate fibroblasts and epithelial cells. Neutrophils also produce high levels of protease (elastase and collagenase)

that can clean up damaged extracellular matrix components.³ Generally, the number of neutrophils in a tissue begins to increase in the first 24–48 hours after injury, reaching a peak at 2–3 days and then decreasing thereafter through the process of apoptosis. In inflammatory conditions with infection, the number of tissue neutrophils can last longer and lead to an elongated wound healing process.¹⁸

Various studies have shown that micronutrients such as zinc, calcium, magnesium, manganese, and iron are required in the wound healing process. Micronutrient deficiency is associated with prolonged wound healing process and the occurrence of chronic wounds. Zinc plays a role in various stages of wound healing including platelet activation, polymorphonuclear influx, re-epithelial processes, angiogenesis, and extracellular matrix remodeling.¹⁹ Magnesium can improve insulin sensitivity and blood sugar regulation that play a role in the healing process of diabetic wounds.²⁰ Calcium is a micronutrient that plays a role in the homeostasis of skin tissue in mammals. Locally, calcium can modulate proliferation, maturation, and cell motility through transduction signals and gene expression in the process of epidermal regeneration and dermal reconstruction in wound healing.²¹ Iron plays a role in the process of angiogenesis in wound healing.²²

In this study, it was found that the number of tissue neutrophils in the control and extract groups increased on day 3 and decreased on day 10, although there were no significant differences in both groups. The average number of neutrophils in the control group on days 0, 3, and 10 were higher compared to the extract group.

In the proliferation phase, there are several processes that occur including matrix turnover to restore tissue structure and function, angiogenesis processes, and granulation tissue formations that lead to re-epithelialization processes. Migration and accumulation of fibroblasts in the wound area play a role in the movement from the extracellular matrix to the wound area.⁵

This study showed that the number of tissue fibroblasts in the control and extract groups increased on days 3 and 10 with statistically significant differences on day 3 where the number of fibroblasts of the extract group was higher than the control group. Similar results were obtained in a previous study that showed the administration of snakehead fish extract increased the number of fibroblasts and expression of fibroblast growth factor-2 (FGF-2) in the healing process of oral mucosa of the Wistar rats. Fibroblasts regulate angiogenesis via secretion of FGF-2.¹⁶ Snakehead fish extract contains zinc and calcium that can stimulate fibroblasts in tissue healing. Zinc plays an important role in the proliferation phase by stimulating fibroblast infiltration and extracellular matrix deposit.¹⁹ Calcium modulates proliferation and maturation of dermal structures in the wound area.²¹

The process of angiogenesis is stimulated by local factors including low oxygen pressure, low pH, and high lactate levels. VEGF is the primary vascular growth factor in the entire angiogenesis process.^{3,23} Iron grade has a positive effect on wound healing by increasing VEGF and HIF1- α and contains functional proteins that play a role in collagen metabolism and extracellular matrix by procollagen-proline dioxygenase.²²

Our study showed that the number of vascular tissues in the control and extract groups increased on day 3 and decreased on day 10, despite no significant differences in both the groups. From this data, it can be concluded that snakehead fish extract does not affect the vascular tissue significantly in the wound healing process. Dose adjustment and assessment of anemia status in samples were required to assess iron requirements in rats, given the previous studies that assessed the effect of iron on wound healing using different doses, methods of application, and anemia status.^{22,24}

Macroscopically the extract group had a smaller erythema visual score than the control group, especially on day 3. Even though not significant, the formation of crust in the extract group on day 3, 5, and 7 had smaller visual score compared to control group. These macroscopic results showed that the extract group had lesser erythema on day 3 and fewer crust formation compared to the control group.

The limitation of this study is lack of tissue examination days (Microscopic changes in skin tissue can occur rapidly, especially during the inflammatory and proliferative phase, so histological examination should be done on a regular basis). Therefore, more routine tissue examination is needed to better assess histological changes in the wound healing process. The longer duration of snakehead fish extract intake can affect the result of the study.

Conclusion

In hyperglycemic rats, oral administration of snakehead fish extract significantly increased the number of fibroblasts in the proliferation phase of the acute wound healing process. Although insignificant, snakehead fish extract can also decrease the number of neutrophils of wound tissue in the inflammatory phase of acute wounds. Macroscopically,

decreased erythema and fewer crust formation were seen in intervention group compared to control group. Therefore, snakehead fish extract has potential benefits and can be used to support the healing process of acute wounds in hyperglycemic conditions.

Data availability

Underlying data

Figshare: 18 Underlying data for 'The effect of snakehead fish extract on acute wound healing process in hyperglycemic rats'. <https://doi.org/10.6084/m9.figshare.19146155.v1>.²⁶

The project contains the following underlying data:

- Raw data for 'The effect of snakehead fish extract on acute wound healing process in hyperglycemic rats'.

Reporting guidelines

Figshare: ARRIVE checklist for 'The effect of snakehead fish extract on acute wound healing process in hyperglycemic rats'.

<https://doi.org/10.6084/m9.figshare.19146260.v1>.²⁷

Data are available under the terms of the Creative Commons Zero "No rights reserved" data waiver (CC0 1.0 Public domain dedication).

Author contributions

Nurpudji Astuti Taslim: Conceptualization, Funding Acquisition, Investigation, Supervision, Validation, Writing – Review & Editing; Caroline Prisilia Marsella: Writing – Review & Editing; Agusssalim Bukhari: Validation, Writing – Review & Editing; Muhammad Husni Cangara: Validation, Writing – Review & Editing; Andi Makbul Aman: Validation, Writing – Review & Editing; Aminuddin: Validation, Writing – Review & Editing; Mardiana Madjid: Validation, Writing – Review & Editing.

Acknowledgement

We thank all contributors, especially Hasanuddin University Research and Community Services for support.

References

1. Stojadinovic O, Brem H, Fallon J, et al.: **Molecular Pathogenesis of Chronic Wounds: The Role of β -Catenin and c-myc in the Inhibition of epithelialization and wound healing.** *Am. J. Pathol.* 2005; **71**(1): 59–67.
2. Brem H, Tomic-canic M: **Cellular and molecular basis of wound healing in diabetes.** *J. Clin. Invest.* 2007; **117**(5): 1219–1222. [PubMed Abstract](#) | [Publisher Full Text](#)
3. Schultz G, Moldawer L, Diegelmann R: **Principles of wound healing.** Fritridge R, Thompson M, editors. *Mechanisms of vascular disease.* Adelaide: University of Adelaide Press; 2011.
4. Siswanto A, Dewi N, Hayatie L: **Effect of haruan (channa striata) extract on fibroblast cells count in wound healing.** *J. Dentomaxillofac. Sci.* 2016; **1**(2): 1–6.
5. Cavalcant G, de Paula R, de Souza L, et al.: **Experimental model of traumatic ulcers in the cheek mucosa of rats.** *Acta Cir. Bras.* 2011; **26**(3): 227–234. [Publisher Full Text](#)
6. Hendriati L, Kuncorojakti S, Widodo T, et al.: **The Influence of Channa Striata Extract Emulgel on Incision Wound Healing in White Rats.** *Trad. Med. J.* 2019; **24**(3): 210–215. [Publisher Full Text](#)
7. Srinivasan K, Ramarao P: **Animal models in type 2 diabetes research: An overview.** *Indian J. Med. Res.* 2007; **125**(2007): 451–472.
8. King AJ: **The use of animal models in diabetes research.** *Br. J. Pharmacol.* 2012; **166**: 877–894. [PubMed Abstract](#) | [Publisher Full Text](#)
9. Masson-Meyers DS, Andrade TAM, Caetano GF, et al.: **Experimental models and methods for cutaneous wound healing assessment.** *Int. J. Exp. Pathol.* 2020; **101**(1–2): 21–37. [PubMed Abstract](#) | [Publisher Full Text](#)
10. IACUC: **Anesthesia (Guideline) - Vertebrate animal research.** American Association for Laboratory Animal Science; 2020. [Reference Source](#)
11. Laurence D, Bacharach A: **Evaluation of drug activities: pharmacometrics.** New York: Academic Press Inc; 1964; volume 1: 161 p.
12. Fauzan MR, Dahlan CK, Taslim NA, et al.: **The effect of giving fish extract (Pujimin Plus) on intake of protein and hemoglobin hypoalbuminemic patients.** *Enferm. Clin.* 2020 Jun; **30**: 452–455. [Publisher Full Text](#) | [Reference Source](#)
13. Masoko P, Picard J, Eloff JN: **The use of a rat model to evaluate the in vivo toxicity and wound healing activity of selected Combretum and Terminalia (Combretaceae) species extracts.** *Onderstepoort J. Vet. Res.* 2010; **77**(1): E1–E7. [PubMed Abstract](#) | [Publisher Full Text](#)
14. Kuhlmann M, Wigger-Alberti W, Mackensen YV, et al.: **Wound healing characteristics of a novel wound healing ointment in an abrasive wound model: A randomised, intra-individual clinical investigation.** *Wound Med.* 2019; **24**(1): 24–32. [Publisher Full Text](#)
15. Apriasari ML, Ainah Y, Febrianty E, et al.: **Antioxidant Effect of Channa Micropeltes in Diabetic Wound of Oral Mucosa.** *Int. J. Pharmacol.* 2019; **15**(1): 137–143.

16. Centaryo G, Soesilawati P: **Acceleration of fibroblast number and FGF-2 expression using Channa striata extract induction during wound healing process: in vivo studies in wistar rats.** *Dent. J.* 2016; **49**(56): 125–132.
17. Wijaya I, Taslim NA, Natzir R, et al.: **Molecular and Immunological Mechanisms of Channa striata in Diabetic Wound Healing.** *Int. J. Pharm. Res.* 2020 Nov 2; **12**(sp2).
[Publisher Full Text](#) | [Reference Source](#)
18. Kim M, Liu W, Borjesson DL, et al.: **Dynamics of Neutrophil Infiltration during Cutaneous Wound Healing and Infection Using Fluorescence Imaging.** *J. Invest. Dermatol.* 2008; **128**(7): 1812–1820.
[PubMed Abstract](#) | [Publisher Full Text](#)
19. Lin PH, Sermersheim M, Li H, et al.: **Zinc in wound healing modulation.** *Nutrients.* 2018; **10**(1): 1–20.
20. Razzaghi R, Pidar F, Momen-Heravi M, et al.: **Magnesium Supplementation and the Effects on Wound Healing and Metabolic Status in Patients with Diabetic Foot Ulcer: a Randomized, Double-Blind, Placebo-Controlled Trial.** *Biol. Trace Elem. Res.* 2018; **181**(2): 207–215.
[PubMed Abstract](#) | [Publisher Full Text](#)
21. Lansdown ABG: **Calcium: A potential central regulator in wound healing in the skin.** *Wound Repair Regen.* 2002; **10**(5): 271–285.
[PubMed Abstract](#) | [Publisher Full Text](#)
22. Wright JA, Richards T, Srai SKS: **The role of iron in the skin and cutaneous wound healing.** *Front. Pharmacol.* 2014; **5**(July): 1–8.
[Publisher Full Text](#)
23. Bates DO, Jones ROP: **The International Journal of Lower Extremity The Role of Vascular Endothelial Growth Factor in Wound Healing.** *Int. J. Low Extrem Wounds.* 2003; **2**(2): 107–120.
[Publisher Full Text](#)
24. Mohammadpour M, Behjati M, Sadeghi A, et al.: **Wound healing by topical application of antioxidant iron chelators: kojic acid and deferiprone.** *Int. Wound J.* 2013; **10**: 260–264.
[PubMed Abstract](#) | [Publisher Full Text](#)
25. Chan JK: **The wonderful colors of the hematoxylin-eosin stain in diagnostic surgical pathology.** *Int. J. Surg. Pathol.* 2014; **22**(1): 12–32.
[PubMed Abstract](#) | [Publisher Full Text](#)
26. Taslim NA: **RAW Data for The effect of snakehead fish extract on acute wound healing process in hyperglycemic rats.** *figshare.* Dataset. 2022.
[Publisher Full Text](#)
27. Taslim NA: **ARRIVE Guideline for 'The effect of snakehead fish extract on acute wound healing process in hyperglycemic rats'.** *figshare.* Journal Contribution. 2022.
[Publisher Full Text](#)

Open Peer Review

Current Peer Review Status: ? ?

Version 1

Reviewer Report 14 October 2022

<https://doi.org/10.5256/f1000research.120672.r148910>

© 2022 Musa A et al. This is an open access peer review report distributed under the terms of the [Creative Commons Attribution License](#), which permits unrestricted use, distribution, and reproduction in any medium, provided the original work is properly cited.

? **Ahmad Farouk Musa** 

Jeffrey Cheah School of Medicine & Health Sciences, Monash University Malaysia, Bandar Sunway, Malaysia

Shaik Farooq

Jeffrey Cheah School of Medicine & Health Sciences, Monash University Malaysia, Bandar Sunway, Malaysia

Thanks for allowing us to review this manuscript. It is a widely researched topic in this part of the world. We acknowledged that *in vivo* models remain the most predictive model; for studying wound healing that allows for realistic representation of the wound environment. However, we have several comments regarding the manuscript. Our main concern is with regard to the methodology for assessing wound healing in animal subjects.

1. Despite the investigators' assessment of the wound macroscopically in terms of erythema, there is no measurement of the most objective wound healing rate. This is basically the rate of re-epithelialization since the endpoint of a successful treatment is complete and permanent wound closure. This is basically calculated from the rate of change in the wound surface area which is the best way to quantify the healing progress. We note that this is missing from the methodology. The measurement of wound size is considered as the most established marker during a wound follow-up. To assess the wound re-epithelialization or wound healing rate, the equation used is $[(A_i - A_f)/A_i]$ where A_i represents the initial stage of the wound area and A_f represents the final area measured. The wound healing rate or WHR is calculated by multiplying by 100 and would then range from 1-100% representing complete epithelialization while 0% means no sign of re-epithelialization. We believe this is the most objective way of assessing wound healing in animal subjects in such cases but this was sorely missing.
2. While the macroscopic assessment of erythema is acceptable, we find that there is nowhere in the literature that talks about crust formation or lesser crust formation to indicate a better healing process. This is dissimilar to granulation tissue which has been established as a signifier for wound healing.

3. The histological analysis only centred on the most common H&E. While we understand that none of the co-investigators are histopathologists, we feel this was grossly inadequate. Masson's trichrome which would normally stain muscles and intercellular fibres, cytoplasm, and keratin in red; collagen in blue; and nuclei in black in our opinion should also be used.
4. Similarly, we believe that there must be an immunohistochemistry analysis. Assessment of angiogenesis for the wound healing process for example would be made possible by using CD31 & CD 34. After immunostaining, the quantification of new blood vessel density can be determined by counting the stained endothelial cell or calculating the percentage of the total vessel stained area. The average number of blood vessels counted in all fields would provide a microvascular density. Well, we won't go into detail in the process but we believe that an addition of a histopathologist as a co-researcher would have been very helpful.
5. The dose of streptozotocin should be in mg/kg, 8.5mg for all rats seems a little unfair to the differently sized rats.
6. The authors deduced that the increased number of fibroblasts could be due to the calcium and zinc content in the extract. However, according to table 1, the content of zinc and calcium is relatively low compared to other components of CS extract. Could there be other contributing factors besides zinc and calcium?
7. "Iron grade has a positive effect on wound healing by increasing VEGF and HIF1- α and contains functional proteins that play a role in collagen metabolism and extracellular matrix by procollagen-proline dioxygenase." This sentence is confusing, what does iron grade refer to?
8. There is a lack of discussion about the results of the erythema visual score and crust formation. Authors can discuss why these results are observed and relate it to CS extract and other studies with similar results.

Is the work clearly and accurately presented and does it cite the current literature?

Yes

Is the study design appropriate and is the work technically sound?

Partly

Are sufficient details of methods and analysis provided to allow replication by others?

Yes

If applicable, is the statistical analysis and its interpretation appropriate?

Yes

Are all the source data underlying the results available to ensure full reproducibility?

Yes

Are the conclusions drawn adequately supported by the results?

Partly

Competing Interests: No competing interests were disclosed.

Reviewer Expertise: Ahmad Farouk Musa - Clinical Trials Shaik Farooq - Pharmacology

We confirm that we have read this submission and believe that we have an appropriate level of expertise to confirm that it is of an acceptable scientific standard, however we have significant reservations, as outlined above.

Reviewer Report 10 August 2022

<https://doi.org/10.5256/f1000research.120672.r146807>

© 2022 Abdunnur A. This is an open access peer review report distributed under the terms of the [Creative Commons Attribution License](#), which permits unrestricted use, distribution, and reproduction in any medium, provided the original work is properly cited.



Abdunnur Abdunnur

Department of Aquatic Resources Management, Faculty of Fisheries and Marine Science, Mulawarman University, Samarinda, Indonesia

Manuscript by *Taslim et al.* this paper presents the results of the intervention of snakehead fish extract or Pujimin Plus® on acute wound healing process in hyperglycemic rats. This is an *in vivo* study on experimental animals.

This manuscript seems to need some improvements before the indexation process continues, as follows:

1. Abstract, in the introduction section, the extract obtained already has the market brand "(Pujimin Plus®)". This should be mentioned in the objective section of this abstract.
2. In the introduction, please:
 - Add the appropriate reference citation in the sentence, "Snakehead fish (*Channa striata*), a native freshwater fish in South East Asia, contains high protein and albumin which act as antioxidants and constitutive tissue components." and "Snakehead fish also contains micronutrients such as zinc, iron, calcium, and magnesium which have role in the immune system and wound healing process."
 - Because researchers have developed a snakehead fish extract formula with the brand "Pujimin Plus®". Please be consistent in quoting brands. Each word snakehead fish extract is followed by the brand word "(Pujimin Plus®)" and this applies throughout the main manuscript.
3. Method:
 - Please provide a description of the nutrition facts of the given diet/pellet.
 - Need a description of how the Pujimin Plus® formula is?
 - What is the reason why researchers use a dose of 81 mg/day?

- How many doses of Na-CMC were given to the control group? Please state clearly.
 - Who is the holder of this patent or trademark of Pujimin Plus®? This needs to be in state to identify conflicts of interest.
 - Where did the data in table 1 come from? If referring to other research, please state the citation. If you do it by authors, please provide details of the test method. Please clarify.
4. In the Introduction section there is a statement "However, the exact mechanism of how this extract improves wound healing remains unclear." I hope the author can provide pictures that support the explanation of how the exact mechanism of snakehead fish extract or (Pujimin Plus®) in the wound healing process. This will make it easier for readers to understand.

Is the work clearly and accurately presented and does it cite the current literature?

Partly

Is the study design appropriate and is the work technically sound?

Partly

Are sufficient details of methods and analysis provided to allow replication by others?

Partly

If applicable, is the statistical analysis and its interpretation appropriate?

Yes

Are all the source data underlying the results available to ensure full reproducibility?

Yes

Are the conclusions drawn adequately supported by the results?

Partly

Competing Interests: No competing interests were disclosed.

Reviewer Expertise: Marine biology and Aquatic Resources Management; Fisheries and Marine Sciences

I confirm that I have read this submission and believe that I have an appropriate level of expertise to confirm that it is of an acceptable scientific standard, however I have significant reservations, as outlined above.

The benefits of publishing with F1000Research:

- Your article is published within days, with no editorial bias
- You can publish traditional articles, null/negative results, case reports, data notes and more
- The peer review process is transparent and collaborative
- Your article is indexed in PubMed after passing peer review
- Dedicated customer support at every stage

For pre-submission enquiries, contact research@f1000.com

F1000Research

15._Agussalim_Bukhari-Nurpudji3.pdf

ORIGINALITY REPORT

23%

SIMILARITY INDEX

17%

INTERNET SOURCES

15%

PUBLICATIONS

10%

STUDENT PAPERS

PRIMARY SOURCES

1	Lusiana Aulia, Yunita Sari Pane. "Effect of Aloe vera extract in post-burn skin repair in rats", F1000Research, 2022 Publication	2%
2	Submitted to University of North Carolina - Wilmington Student Paper	2%
3	Submitted to Universitas Bung Hatta Student Paper	1%
4	Annette Wysocki. "Skin, Molecular Cell Biology of", Encyclopedia of Molecular Cell Biology and Molecular Medicine, 09/15/2006 Publication	1%
5	pdfs.semanticscholar.org Internet Source	1%
6	ljkzedo.ba Internet Source	1%
7	wellcomeopenresearch.s3.eu-west-1.amazonaws.com Internet Source	1%

8	www.journalijar.com Internet Source	1 %
9	www.jurnal.ugm.ac.id Internet Source	<1 %
10	M. Kuhlmann, W. Wigger-Alberti, Y.v. Mackensen, M. Ebbinghaus, R. Williams, F. Krause-Kyora, R. Wolber. "Wound healing characteristics of a novel wound healing ointment in an abrasive wound model: A randomised, intra-individual clinical investigation", Wound Medicine, 2019 Publication	<1 %
11	academic.oup.com Internet Source	<1 %
12	Submitted to King Saud bin Abdulaziz University for Health Sciences Student Paper	<1 %
13	Submitted to Universitas Hasanuddin Student Paper	<1 %
14	Submitted to Universitas Mulawarman Student Paper	<1 %
15	encyclopedia.pub Internet Source	<1 %
16	Layle Rahmiyanti, Haerani Rasyid, Nurpudji Astuti Taslim, Suryani As'ad, Agussalim Bukhari, Aminuddin Aminuddin. "Nutritional	<1 %

Status Associated to Red Cell Distribution Width, Length of Stay, and Clinical Outcome patient with Chronic Kidney Diseases", Open Access Macedonian Journal of Medical Sciences, 2022

Publication

17

Liza Meutia Sari, Zaki Mubarak, Dina Keumala Sari. "Evaluation of clinical, histology, TNF- α , and collagen expressions on oral ulcer in rats after treatment with areca nut and chrysanthemum oral gel", F1000Research, 2021

Publication

<1 %

18

Wonga Laohasiriwong, Sim Samphors, Pall Chamroen, Vong Pisey, Rebecca S. Dewey. "Association between socioeconomic factors and soft drink consumption among adults in Cambodia: a cross-sectional study", F1000Research, 2020

Publication

<1 %

19

Submitted to Southern New Hampshire University - Continuing Education

Student Paper

<1 %

20

escholarship.mcgill.ca

Internet Source

<1 %

21

www.ncbi.nlm.nih.gov

Internet Source

<1 %

22	zennutrients.com Internet Source	<1 %
23	annalsmedres.org Internet Source	<1 %
24	www.scielo.br Internet Source	<1 %
25	journals.plos.org Internet Source	<1 %
26	Feni Fitriani Taufik, Rosdiana Natzir, Ilhamjaya Patellongi, Arif Santoso et al. "In vivo and in vitro inhibition effect of propolis on Klebsiella pneumoniae: A review", Annals of Medicine and Surgery, 2022 Publication	<1 %
27	"Posters", Diabetic Medicine, 12/2006 Publication	<1 %
28	Submitted to Saint Mary's College of California Student Paper	<1 %
29	Submitted to University of North Texas Student Paper	<1 %
30	bsdwebstorage.blob.core.windows.net Internet Source	<1 %
31	Submitted to Saint Leo University Student Paper	<1 %

32	rc.library.uta.edu Internet Source	<1 %
33	www.e-crt.org Internet Source	<1 %
34	www.ebc.ee Internet Source	<1 %
35	www.panafrican-med-journal.com Internet Source	<1 %
36	Alan B. G. Lansdown. "Calcium: a potential central regulator in wound healing in the skin", <i>Wound Repair and Regeneration</i> , 2002 Publication	<1 %
37	Submitted to University of Northumbria at Newcastle Student Paper	<1 %
38	biomedpharmajournal.org Internet Source	<1 %
39	e-journal.unair.ac.id Internet Source	<1 %
40	jacobspublishers.com Internet Source	<1 %
41	www.gssrr.org Internet Source	<1 %
42	www.hindawi.com Internet Source	<1 %

43

www.pure.ed.ac.uk

Internet Source

<1 %

44

Ahmad Farouk Musa, Xian Pei Cheong, Jeswant Dillon, Rusli Bin Nordin. "Validation of EuroSCORE II in patients undergoing coronary artery bypass grafting (CABG) surgery at the National Heart Institute, Kuala Lumpur: a retrospective review.", F1000Research, 2019

Publication

<1 %

45

P. Masoko, J. Picard, R. L. Howard, L. J. Mampuru, J. N. Eloff. " antifungal effect of and species extracts on cutaneous wound healing in immunosuppressed rats ", Pharmaceutical Biology, 2010

Publication

<1 %

46

link.springer.com

Internet Source

<1 %

47

Dwi Pudjonarko, Retnaningsih, Zainal Abidin. "Clinical Outcome And Arginine Serum of Acute Ischemic Stroke Patients Supplemented by Snakehead Fish Extract", IOP Conference Series: Earth and Environmental Science, 2018

Publication

<1 %

48

Masoko, Peter, Jacobus N. Eloff, and Jackie Picard. "The use of a rat model to evaluate the in vivo toxicity and wound healing activity of selected Combretum and Terminalia

<1 %

(Combretaceae) species extracts",
Onderstepoort Journal of Veterinary Research,
2010.

Publication

-
- | | | |
|----|--|------|
| 49 | Takdir Tahir, Nur Febrianti, Sri Wahyuni, Rabia, Yuliana Syam. "Evaluation of acute wound healing potential of red dragon fruit (<i>Hylocereus Polyrhizus</i>) extract cream on type III collagen and Epidermal Growth Factor (EGF) levels: An animal study", <i>Medicina Clínica Práctica</i> , 2020
Publication | <1 % |
| 50 | archrazi.areeo.ac.ir
Internet Source | <1 % |
| 51 | discovery.ucl.ac.uk
Internet Source | <1 % |
| 52 | dokumen.pub
Internet Source | <1 % |
| 53 | downloads.hindawi.com
Internet Source | <1 % |
| 54 | onlinelibrary.wiley.com
Internet Source | <1 % |
| 55 | ppsub.ub.ac.id
Internet Source | <1 % |
| 56 | www.awma.com.au
Internet Source | <1 % |
-

57 www.dovepress.com Internet Source <1 %

58 www.issls.org Internet Source <1 %

59 www2.mdpi.com Internet Source <1 %

60 "Pathology and Epidemiology of Cancer", Springer Science and Business Media LLC, 2017 Publication <1 %

61 "Final Program and Abstracts of papers presented at the World Federation of Societies of Biological Psychiatry 2004 WFSBP Asia-Pacific Congress and 41st meeting of KSBP, 9–11 July 2004, Seoul, Korea", The World Journal of Biological Psychiatry, 2009 Publication <1 %

62 Ahmad Farouk Musa, Vignaa Prashanth Gandhi, Jeswant Dillon, Rusli Bin Nordin. "A retrospective review on minimally invasive technique via endoscopic thoracic sympathectomy (ETS) in the treatment of severe primary hyperhidrosis: Experiences from the National Heart Institute, Malaysia", F1000Research, 2018 Publication <1 %

Current Clinical Pathology, 2015.

63

Publication

<1 %

64

Imam Mustofa, Suherni Susilowati, Tri Wahyu Suprayogi, Adeyinka Oye Akintunde, Yudit Oktanella, Djoko Agus Purwanto.

<1 %

"Epigallocatechin-3-gallate chitosan nanoparticles in an extender improve the antioxidant capacity and post-thawed quality of Kacang goat semen", F1000Research, 2023

Publication

Exclude quotes On

Exclude matches < 5 words

Exclude bibliography On